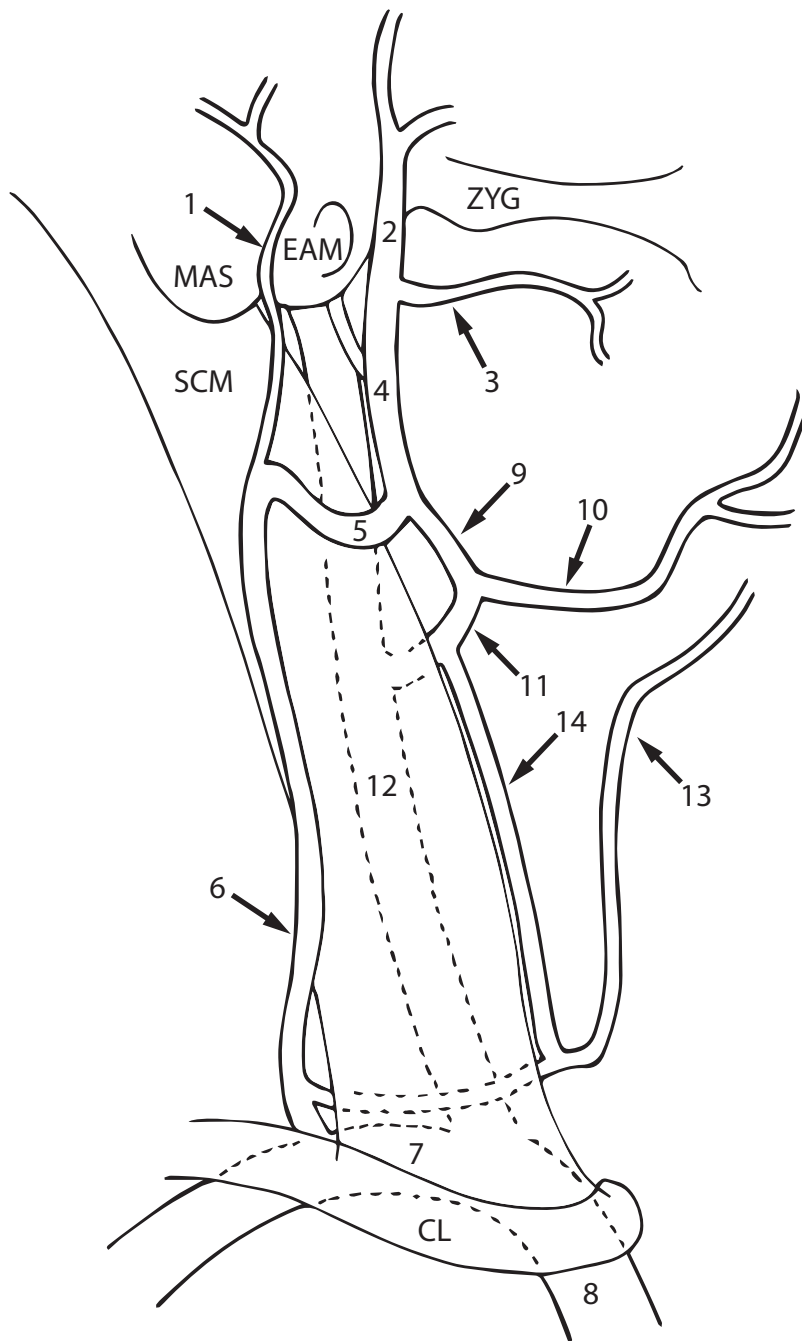


Typical Venous Drainage Pattern of the Face and Neck



- 1 - Posterior Auricular v.
- 2 - Superficial Temporal v.
- 3 - Maxillary v.
- 4 - Retromandibular v.
- 5 - Posterior Division of Retromandibular v.
- 6 - External Jugular v.
- 7 - Subclavian v.
- 8 - Brachiocephalic v.
- 9 - Anterior Division of Retromandibular v.
- 10 - Facial v.
- 11 - Common Facial v.
- 12 - Internal Jugular v.
- 13 - Anterior Jugular v.
- 14 - Communicating Vein

ZYG - Zygomatic Arch
 EAM - External Auditory Meatus
 MAS - Mastoid Process
 SCM - Sternocleidomastoid Muscle
 CL - Clavicle

Lateral View

Note: Veins are notoriously variable and many cadavers will not conform to this pattern. Only major veins are illustrated on this diagram. Dotted lines indicate structures that lie deep to the sternocleidomastoid muscle and clavicle.