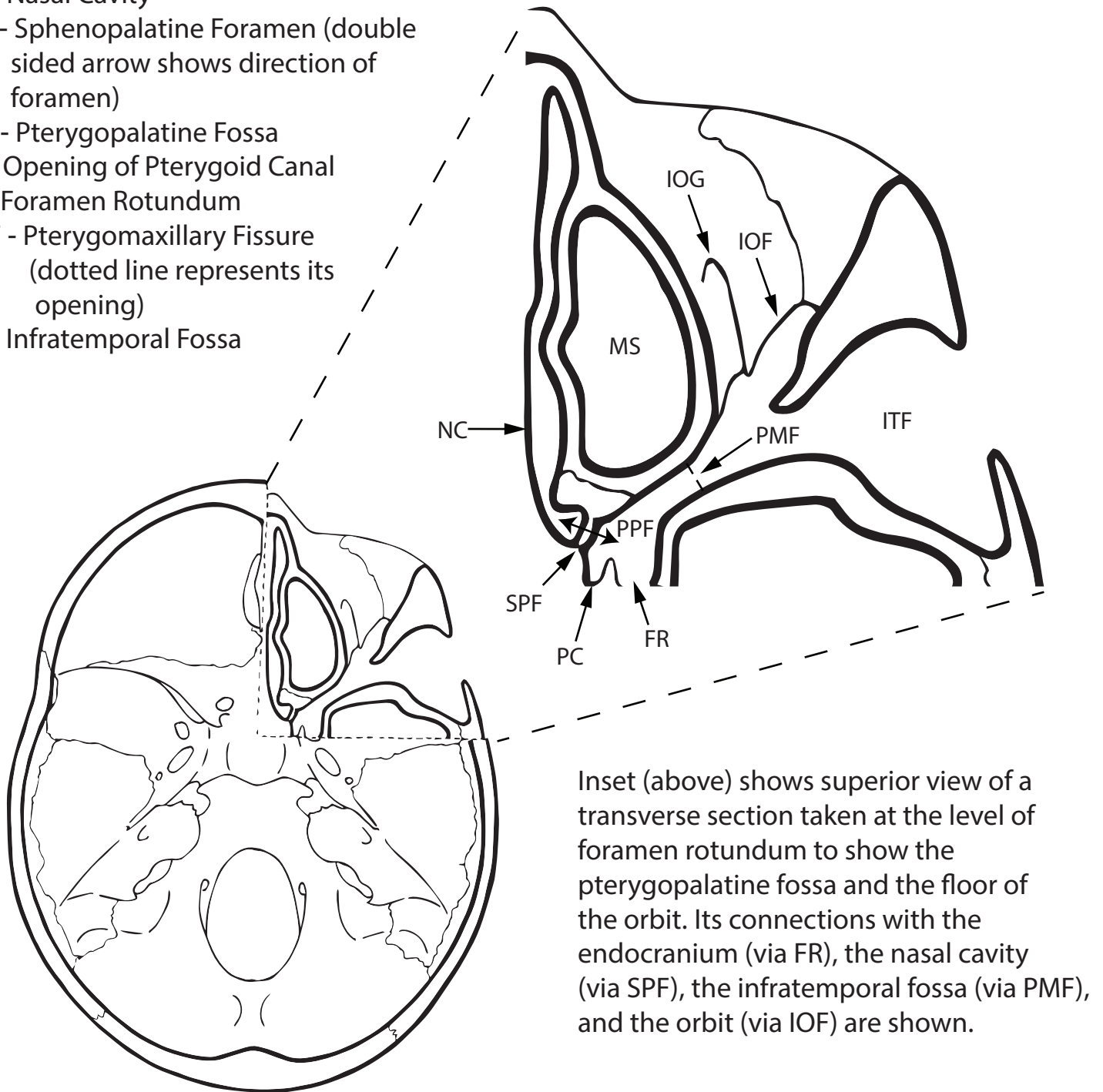


Pterygopalatine Fossa - Openings and Relationships

- IOF - Inferior Orbital Fissure
- IOG - Infraorbital Groove
- MS - Maxillary Sinus
- NC - Nasal Cavity
- SPF - Sphenopalatine Foramen (double sided arrow shows direction of foramen)
- PPF - Pterygopalatine Fossa
- PC - Opening of Pterygoid Canal
- FR - Foramen Rotundum
- PMF - Pterygomaxillary Fissure (dotted line represents its opening)
- ITF - Infratemporal Fossa



Inset (above) shows superior view of a transverse section taken at the level of foramen rotundum to show the pterygopalatine fossa and the floor of the orbit. Its connections with the endocranium (via FR), the nasal cavity (via SPF), the infratemporal fossa (via PMF), and the orbit (via IOF) are shown.

Location of inset is demonstrated on a typical endocranial view of the skull.